

## Dorsal Augmentation Rhinoplasty by Diced Cartilage Graft

Alaa Ibrahim Al-Jorani<sup>1\*</sup>, Hamid Ibrahim Al-Jorani<sup>2</sup>

<sup>1</sup>Al-Hussien Medical City, Kerbala Health Directorate, Ministry of Health, Iraq

<sup>2</sup>Department of Oral and Maxillofacial Surgery-College of Dentistry, University of Kerbala, Iraq

### ABSTRACT

Dorsal augmentation in rhinoplasty in competition by multiple methods with developing of high care of medicine standards, that obtained by rapidly developing therapies and technological advances. Surgeons, through many years, have tried to evolve the outcomes of dorsal augmentation, by using different types of alloplastic and autologous materials, which include cartilage, bone and diced cartilage. Many surgeons prefer the using of the grafts which is autologous in the orderliness of dorsal augmentations in mild to moderate amounts, for nasal dorsal augmentation, cartilage and bone are considered as autologous source which are employed for this procedure.

A total number of the patients that participated in this study were 50 patients (36 female(72%) and 14 male (28%), age of patients ranged between (19-47 years) whom underwent rhinoplasty of primary, revision and the nasal dorsum with secondary deformities, by using diced cartilage grafts through the open surgical approach. A reconstructive and plastic surgeon led the surgical team for all rhino pasties that were done in this study. The surgical technique was open rhinoplasty for all cases that was included in this study. Cartilage was harvested from the septum, rib, or concha. The nasal septum deviation that associated with cases was corrected at the same time, when the nasal septal cartilage was used as donor site of harvested cartilage. The nasal septal cartilage was used as donor site for harvested cartilage in 39 patients, nasal septal and conchal cartilages were used in 7 patients, and costal cartilage only was used in 4 patients. Three months was the minimum period of follow up, while seventeen months was the average period of follow-up. The complications were experienced in three patients, which included visible graft bulging in the rhinion area that was noticed in these patients. No graft resorption was noticed or observed in any of these three patients, patients were followed -up by serial photography, serial physical examination, and input was received from the patients. Augmentation rhinoplasty that use autogenous diced cartilage has good advantage result from malleability and easy insertion of this type of graft. Good results obtained from use the diced cartilage without wrapping of it in other material like Surgical or fascia with less or not complications such as cartilage resorption or warping.

**Key words:** Augmentation rhinoplasty, Diced cartilage, Nasal dorsum

**HOW TO CITE THIS ARTICLE:** Alaa Ibrahim Al-Jorani, Hamid Ibrahim Al-Jorani, Dorsal Augmentation Rhinoplasty by Diced Cartilage Graft, J Res Med Dent Sci, 2022, 10 (11): 115-122.

**Corresponding author:** Alaa Ibrahim Al-Jorani

**e-mail** ✉: dralaaajorani@gmail.com

**Received:** 08-Oct-2022, Manuscript No. JRMDs-22-79303;

**Editor assigned:** 10-Oct-2022, PreQC No. JRMDs-22-79303(PQ);

**Reviewed:** 24-Oct-2022, QC No. JRMDs-22-79303(Q);

**Revised:** 28-Oct-2022, Manuscript No. JRMDs-22-79303(R);

**Published:** 04-Nov-2022

### INTRODUCTION

In the field of esthetic plastic surgery, rhinoplasty is considered as the most difficult and common surgical procedure [1]. Augmentation rhinoplasty is chiefly depending on the procedure by which we use either implants material (alloplastic) or autologous grafts to restore the height of the nasal dorsum and to correct nasal skeleton defect. Alloplastic implants and autologous

graft are considered the main sources are available for dorsal augmentation. The choice of the material for dorsal augmentation depends on the: the amplitude of the deficiency in the nasal dorsum, associated structural deformities, skin and overlying soft tissue, previous surgery history, body response, properties of implants, its advantages and limitations, views of the patient, and preferences of the plastic surgeon [2]. Dorsal augmentation rhinoplasty in competition by multiple procedures with developing of high care of medicine standards, that obtained by rapidly developing therapies and technological advances [3]. Surgeons, through many years, have tried to evolve the outcomes of dorsal augmentation, by using a different types of alloplastic and autologous materials, which include: Cartilage, bone [4-6], diced cartilage and fascia [7-11], medpore [12], silicone [13-15], vicryl [16], polytetrafluoroethylene [17,18], supramid [19], and proplast [20].

Many surgeons prefer the using of the grafts which is autologous in the orderliness of dorsal augmentations in mild to moderate amounts; for nasal dorsal augmentation, cartilage and bone are considered as autologous source which are employed for this procedure [13,21]. In rhinoplasty, cases that demand large volume of graft materials have provoked or encouraged the surgeons to find or explore alloplastic materials like (silicone, Goretex, etc.).

For nasal dorsal augmentation, cartilage and bone are considered as autologous source which are employed for this procedure. In rhinoplasty, cartilage grafts have employed for multiple applications such as: restoring alar contour, spreader graft, tip & columellar strut, crural strut (lateral), nasal septum extension, and dorsal augmentation. Bone grafts are usually well tolerated, but they tend to be an unnatural and appears like a rigid structure to the reconstructed nose [22]. Implant materials (alloplastic) that were employed for reconstruction of dorsum of the nose, have a large variety, so that the optimal alloplastic materials selection is still to be in a challenge [23].

During rhinoplasty, in dorsal augmentation, in the literature of the English-language, the using of the diced cartilage has been documented early by Peer (1943), Cottle (1951), and by Burian (1968), wide acceptance for this procedure at that time did not achieve [24-26]. This concept was revisited by Guerrerosantos in the 1990s [9], the technique refinement was done by using the fascia for wrapping of the fragmented cartilage. In 2000 [27], a larger assembly was brought by Erol with his method, which included the use of the Surgical for wrapping diced cartilage. The use of the fascia for wrapping diced cartilage, brought a renewed interested by Daniel, et al. [7,8]. Renewed interest in diced cartilage in rhinoplasty has emerged in recent years [28,29]. The surgeons were attracted toward the use of the cartilage in diced form rather than the use of the cartilage in solid piece, for many reasons such as : greater flexibility of diced cartilage, preclude the requirement of single large graft and warping with minimal risks. Diced cartilage, fascia is used for wrapping diced cartilage and fascia is used for covering diced cartilage, are considered as different methods has been employed to use the diced cartilage [30]. Considerable interest has been existed in the function of diced cartilage grafts for augmentation of the nasal dorsum, but predictability of molding the diced cartilage in coveted form and the viability of cartilage (diced) for long-term, controversy exists to the diced cartilage grafts for augmentation of dorsum of the nose [31].

#### METHOD AND PATIENTS

This study was done at reconstructive and plastic surgery unit in Al-Husien medical teaching city and Al-Kafeel hospital in Karbella governorate in Iraq. Between January 2015 and July 2018, a total number of the patients that participated in this study were 50 patients (36 female(72%) and 14 male (28%)), age of patients

ranged between (19-47 years) whom underwent rhinoplasty of primary, revision and the nasal dorsum with secondary deformities, by using diced cartilage grafts through the open surgical approach. All patients under went open rhinoplasty under general anesthesia.

All patients that included in this study had healthy systemic conditions and appropriate for surgical procedure and general anesthesia. Real expectation of the primary, secondary, or revision rhinoplasty was requested for all patients, and accepted for morbidities such as scar in donor site or infection of the wound e, and this was documented by informed consent was prepared for this study.

Patients who had over expectations and patients with chronic illnesses like diabetes mellitus, hypertension, cardiac disease, hepatic dysfunction, renal disease, and bleeding tendency were excluded from this study.

Dorsal augmentation preparation and surgical planning starts with the pre-operative visit and consultation, the assessment of the anatomy of the nose should be done and the definition of the aesthetic goals of surgery, with special attention directed to the dorsum of the nose, all these should be established with the patient.

Upper lateral cartilages confluence along the dorsal septum creates the shape platform and integrity which is considered the primary consideration in relation to the pre-operative anatomy of the nose. Proper preparation and the dorsum modification to get support for diced cartilage is indicated in the presence of noticeable contour irregularities such as an inverted-V deformities or dorsal hump.

Pre-operatively, upright position is used to mark the patient, the midline of the face, the anticipated nasal starting point, desired supratip break, and dorsal convexity (if present) should be marked, also the xiphoid and inframammary/infracreast crease should be marked when we need to harvest the costal cartilage.

A reconstructive and plastic surgeon led the surgical team for all rhino pasties that were done in this study. Open technique for rhinoplasty was done for all cases included in this study. Under general anesthesia, all patients had undergone rhinoplasty procedures with endotracheal intubation and the patient head had fixed on head ring in supine position.

Inverted V shaped incision (trans-columellar) was connected to a bilateral rim incision that leads to expose the osteocartilaginous dorsum of nose (Figures 1 and 2).

Cartilage was harvested from the septum, rib, or concha. The nasal septum deviation was corrected at the same time,when cartilage was harvested from nasal septal cartilage. Costal or chonchal cartilage was harvested, when the septal cartilage was deficient or not sufficient, Obtained harvested cartilage graft was softened by put in the normal saline then the cartilage was diced into (0.5-1.0 mm) cubes by using no. 15 blade. Tuberculin syringe (1.0 cc) with amputated hub is used for filling and packing of diced cartilage (Figure 3).

The graft form and its final position were proceeded by

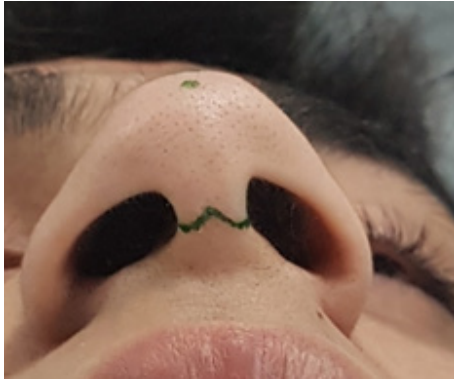

Figure 1: Inverted V shaped incision (trans-columellar).

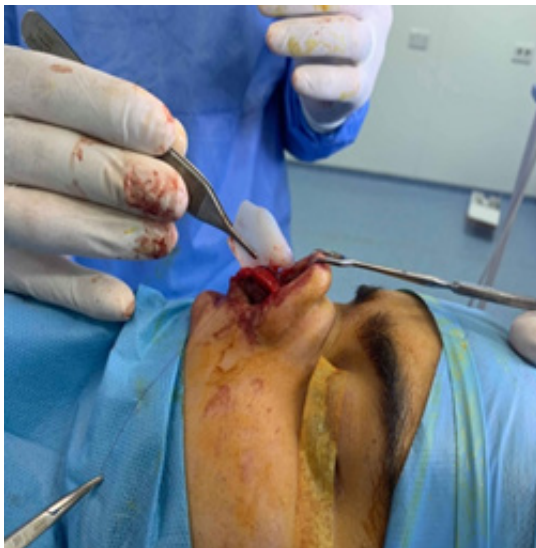

Figure 2: Inverted V shaped incision (Intraoperatively).

external manual manipulation either after nose closure or before closure the diced cartilage can be injected. The ratio of the graft-to-defect was 1:1 by volume, without any overcorrection. Strips of micropores plaster and a flexible metallic or thermoplastic splint were put up over the pyramid of the nose which helps in maintaining the graft in correct position. At least 10 days the splint was left in its place to secure the graft position. Prophylactic antibiotic was given for all patients for 5 days (Figure 4). At 10 days postoperatively, the splint was removed to assess and make, if necessary, minor changes in the dorsal contour by gentle manual pressure on the graft.

## RESULTS

A 50 patients participated in this study, 36 females (72%) and 14 males (28%) ages of these patients were ranged from (19-47 years), open rhinoplasty was done for all these patients under general anesthesia after full investigations like blood film, ECG and chest X-ray; with physician and anesthesiologist consultation in addition to the informed consent were obtained preoperatively.

### Donor site

The nasal septal cartilage was used as donor site for harvested cartilage in 39 patients, nasal septal and

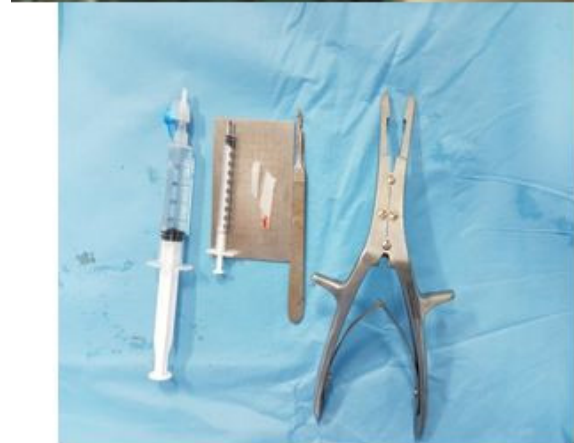
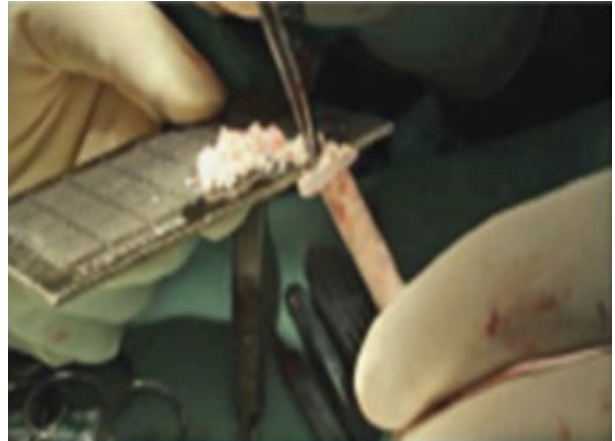
Figure 3: Tuberculin syringe is used for filling and packing of diced cartilage.

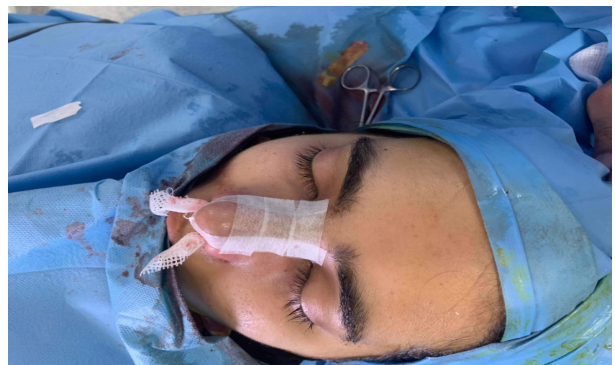

Figure 4: Micropores plaster strips.

conchal cartilages were used in 7 patients, and costal cartilage only was used in 4 patients (Table 1).

### Surgical procedure

A 35 patients were primary rhinoplasty, 9 were secondary rhinoplasty, and 6 were revision Rhinoplasty (Table 2). All patients that participated in this study did not develop any intra-operative complications and complications of donor site after surgery did not happen. Three months was the minimum period of follow up, while seventeen months was the average period of the follow-up (Figures 5 to Figure 9). The complications were experienced in three patients, which included visible graft bulging in the rhinion area that was noticed in these patients. No



Table 1: Donor site.

No. of patients	Gender of patients		Donor sites of diced cartilage		
	Male	Female	Septal	Conchal	Costal
50	36(72%)	14(28%)	39	7	4

Table 2: Surgical procedure.

Total no. of patients or cases	Diced cartilage for Rhinoplasty				
	Surgical procedure		Type of rhinoplasty		
	Open rhinoplasty	Closed rhinoplasty	Primary rhinoplasty	Secondary rhinoplasty	Revision rhinoplasty
50	50	-	35 cases	9 cases	6 cases

Table 3: Follow up.

Total no. of patients	Three months follow up after rhinoplasty			
	Without complications	Complications		
		Dorsal surface irregularities	Protruding of graft	Resorption of graft
50	37	2	1	

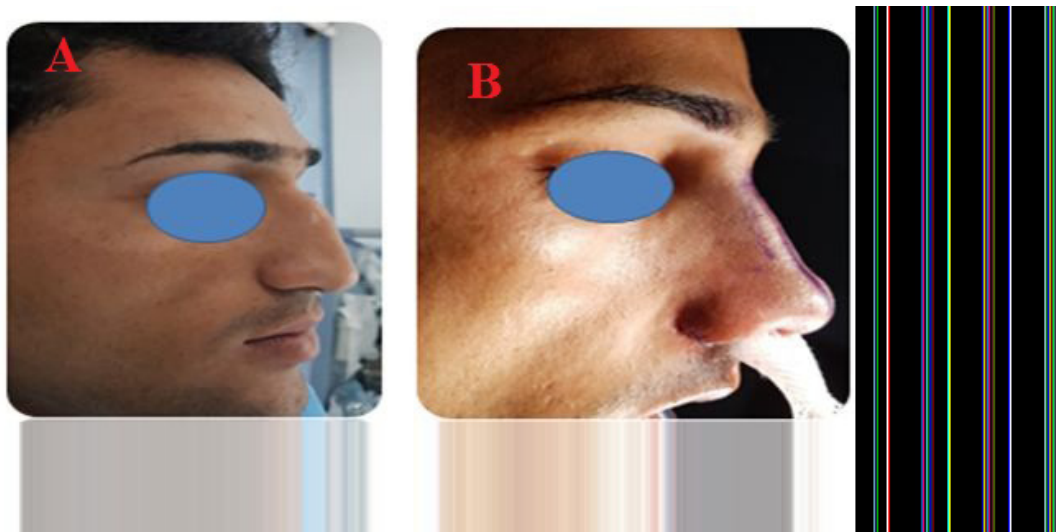


Figure 5: (a) Preoperative pictures (b) Postoperative pictures.

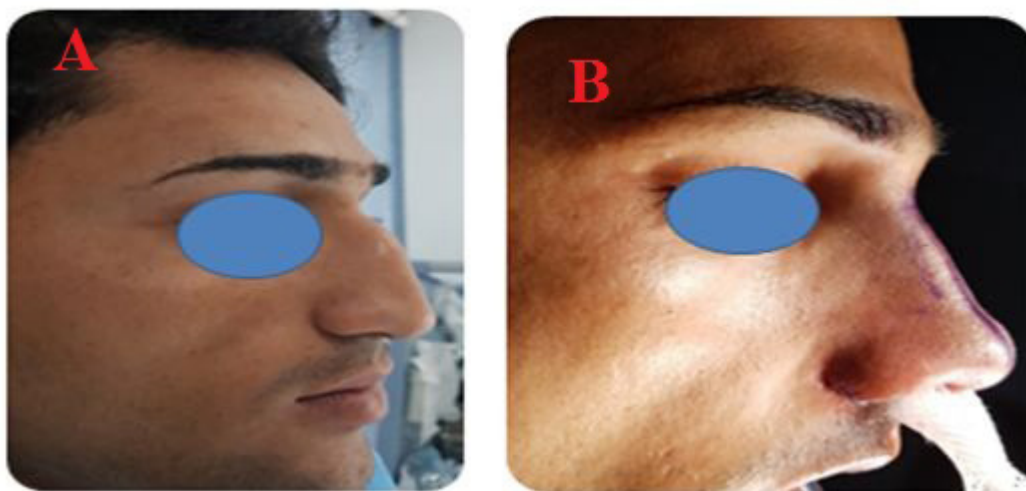


Figure 6: Preoperative pictures (b) Postoperative pictures.

graft resorption was noticed or observed in any of these three patients, patients were followed –up by serial photography, serial physical examination, and input was received from the patients.

Revision was required for one of these three patients (that experienced complications), by revision, the graft protruding parts were flattened to obtain the same level of the dorsum of nose (Figure 10). The smaller dorsum

irregularities in other two patients were corrected by Daniel method that used a 23-gauge needle for grafts punching to correct these dorsum irregularities (Table 3).

### DISCUSSION

A competent structural support of the nose is obtained

by nasal skeleton reconstruction, which allows the perfect function of the nasal airway and consummating or achieving results which are aesthetically pleasing with the remainder parts of the face; these are considered the main aims of septorhinoplasty. Correction of nasal deformity by augmentation rhinoplasty is considered one of the most requested surgical procedures in plastic

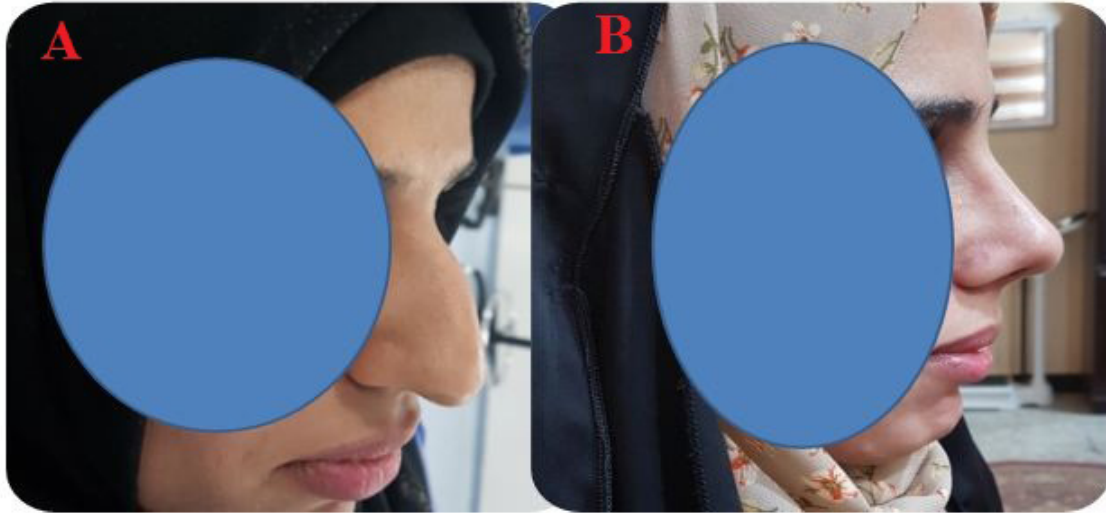


Figure 7: Preoperative pictures (b) Postoperative pictures.

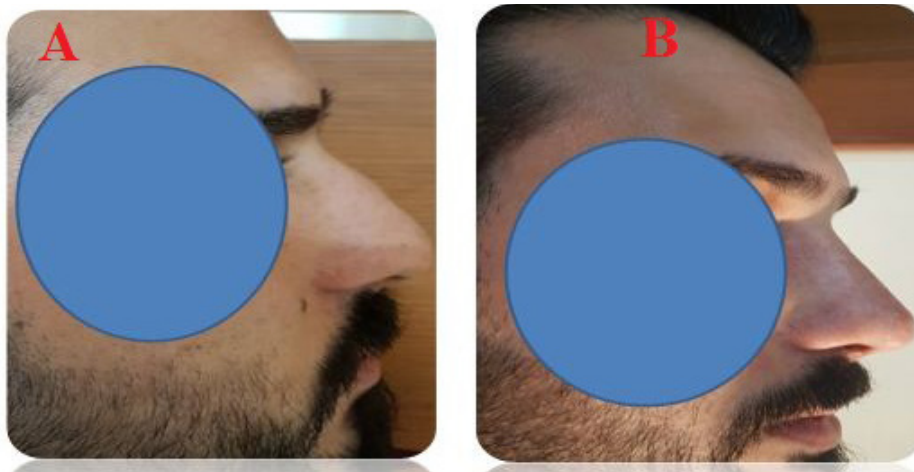

Figure 8: Preoperative pictures (b) Postoperative pictures.

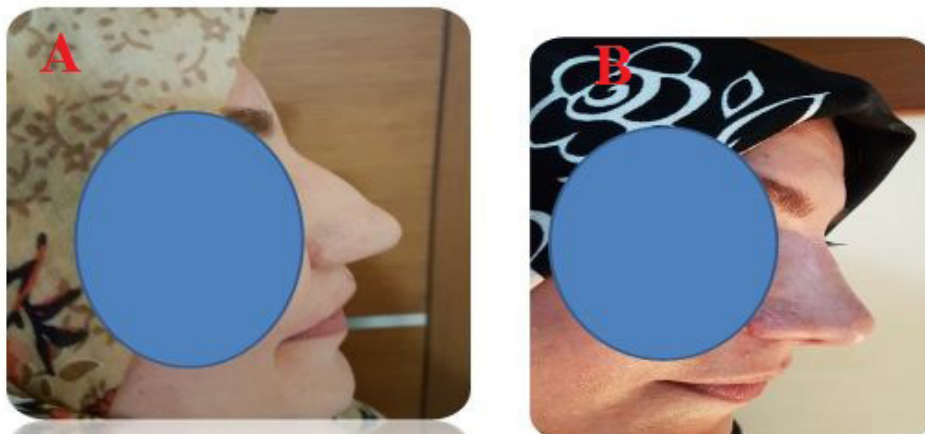


Figure 9: Preoperative pictures (b) Postoperative pictures.

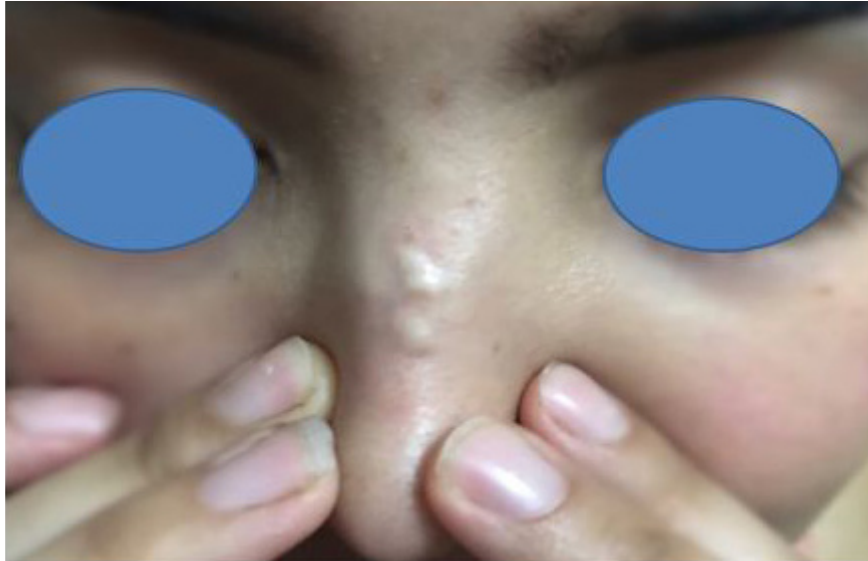

Figure 10: Graft protruding after 3 months follow up.

and reconstructive surgery. Augmentation rhinoplasty requires implants, which are either from natural provenience, like bone, cartilage and dermal graft, or synthetic provenience or materials, like medpore or silicone. The cartilage is considered the gold standard of autogenous grafts because of its durability, deprivation of the immunogenic response; great acceptance rate, with risk of infection and rates of extrusion are depressed [32]. Cartilage graft is widely used in correction of nasal dorsum defects and irregularities, augmentation of low dorsum of the nose, or in any defect in the nose defect in addition to obtain a smooth texture after reconstructive or cosmetic rhinoplasty. Surgeons plan to harvest rib cartilage, in cases requiring large amount of cartilage graft [33]. Four cases in this study the utilized costal cartilage because they need large cartilage for septal augmentation. Peer in 1943, was the first one who gave the description for using the diced cartilage grafts in reconstructive surgery [34].

Side effects were noticed in rigid costal cartilage such as : extrusion of the cartilage, visibility, warping, and complications of donor site, so that diced cartilage graft is employed by plastic surgeons. Diced cartilages grafts have many advantages when they compared with the using of all other forms of cartilages that harvested from nasal septal cartilage or cartilage of external ear during rhinoplasty and without any adverse effects as compared with solid cartilage [35].

In rhinoplasty and revision rhinoplasty, the diced cartilage techniques have been employed and described for over half a century. Diced cartilage techniques has received criticism because of the sausage-like appearance or the unnatural look to the dorsum, which might be developed after surgical technique in spite of it is producing satisfactory results in many cases utilized this technique [36].

Erol in 2000, described the concept of enveloping the dicing cartilage, Surgicel was utilized for wrapping

the diced cartilage and was utilized in augmentation rhinoplasty. Erol gave description for his technique by wrapping the dicing cartilage inside material called Surgicel, this technique was employed in more than 2000 cases of rhinoplasty [37]. Erol's technique had been faced a problem, showed that after three months of graft insertion and follow up, all grafts had been completely resorped and the correction of this problem failed, and that had led to the Erol's technique rejection. Temporalis fascia was introduced by Daniel and Calvert, which is considered as source for enveloping of dicing cartilage [38]. Daniel and Calvert in 2004, used the diced cartilage graft that is enveloped by s temporal fascia (autologous) in augmentation rhinoplasty and they obtained better results. Diced cartilage that was enveloped in surgical, was found inactive from biological aspect and in other side, the diced cartilage that was enveloped in autologous temporal fascia, was found active for the same aspect and had great power of regeneration, these results was obtained by histological analysis [39]. In the last few years, the interest of utilizing diced cartilage technique has begun to raise, also this technique is utilized for reinforcement of rhinoplasty that has been resurfaced. The technique of diced cartilage described the use of cartilage graft in larger pieces [39], but it is also used in smaller pieces not more than (0.2 mm) [40], wrapped or not in Surgicel, fascia (such as autologous temporal fascia) or acellular dermal matrix. The patient's own blood or fibrin glue, sometimes was used to help in aggregation of diced cartilage.

In our study that included 50 cases of dorsal augmentation rhinoplasty, the harvested cartilage, that was taken from septal, costal, and conchal cartilages was diced into 0.5-1 mm cubes to avoid probable resorption of fine pieces of free diced cartilage, and that harmonize or in agreement with Daniel and Calvert [39], who comments in his paper on diced cartilage wrapped with fascia (DCF), ((the smaller the size of diced cartilage, higher is the rate of resorption)), (The described diced cartilage was used



in larger pieces) [39], although it is used as small pieces less than 0.2 mm [40]. Dicing of cartilage by using sharp blades that cut the cartilage into smaller pieces, is less harmful for the cartilage structure. It has been shown in many experimental and clinical studies that the cartilage viability is maintained with time.

In our study, we did not use Surgicil or fascia for wrapping the diced cartilage, cartilage was harvested and diced in cubes and aggregated by patient blood and diced cartilage was inserted under the dorsal skin, (the patient's own blood was used for aggregation of the diced cartilage) [41]. All patients participated in this study, open or classic rhinoplasty was done for them, to implant the free diced cartilage in the dorsum of the nose. Incision and dissection of nasal soft tissues, in the same manner in classic rhinoplasty, is necessary for implantation of free diced cartilage [41].

In our study, three months was the minimum period of follow up, while seventeen months was the average period of the follow-up, cartilage resorption was not recorded in any case, good results obtained in resurfacing of nasal dorsum.

A comparison was done between the viability of the diced cartilage with morselised or crushed cartilage graft in several number of studies that were done on animals, more viable chondrocytes was showed by diced cartilage, with superior results in comparison to another methods of graft preparation [42]. No warping, nasal tip rotation or nasal height loss also was recorded during period of follow up. Diced cartilage typically will choose by surgeons instead of the solid piece of cartilage because the diced cartilage result in much lower risk of warping and allows for more flexibility of graft when compared with solid type [43].

Three cases participated in this study, patients presented with unsatisfied results, they were complaining from the visible bulging of the graft in the rhinion area. Revision was required for one of these three patients (that experienced complications), by revision, the graft protruding parts were flattened to obtain the same level of the dorsum of nose. The smaller dorsum irregularities in other two patients, were corrected by Daniel method, that used a 23-gauge needle for grafts punching to correct these dorsum irregularities.

In the dorsal augmentation rhinoplasty by using diced cartilage, dissatisfaction of surgeon and patient after surgical procedure results from contour irregularities, which are considered the main reason for this dissatisfaction.

Minor contour irregularities are treated, in first month post-surgery, by conservative management and nasal exercises.

The 5-fluorouracil and kenalog directed injections, will successfully treat many of the dorsum irregularities which is noticed in the early period after surgical procedure. Persistent contour irregularities that involve coalesced diced cartilage will require revision surgery [36,44].

## CONCLUSION

Probably the best of fillers that available for concealment different forms of nasal defects is diced cartilage. Augmentation rhinoplasty that use autogenous diced cartilage has good advantage result from malleability and easy insertion of this type of graft. Good results obtained from use the diced cartilage without wrapping of it in other material like Surgical or fascia with less or not complications such as cartilage resorption or warping. Patients' needs further long period of follow up to obtain clear idea about the fate of diced free cartilage in support the nose structure for long time also further studies need to detect the effect of this procedures in cases need large amount of cartilage for augmentation.

## REFERENCES

1. Hackney FL, Gyskiewicz JM. Dorsal augmentation seminar. *Plast Surg* 2008; 22:63-64.
2. Dresner HS, Hilger PA. An overview of nasal dorsal augmentation. In *Seminars in plastic surgery* 2008; 22:65-73.
3. Vilar-Sancho B. An old story: An ivory nasal implant. *Aesthetic Plast Surg* 1987; 11:157-161.
4. Krause CJ. Augmentation rhinoplasty. *Otolaryngol Clin North Am* 1975; 8:743-752.
5. Wheeler ES, Kawamoto HK, Zarem HA. Bone grafts for nasal reconstruction. *Plast Reconstr Surg* 1982; 69:9-18.
6. Romo T, Jablonski RD. Nasal reconstruction using split calvarial grafts. *Otolaryngol Head Neck Surg* 1992; 107:622-630.
7. Daniel RK. *Rhinoplasty: An atlas of surgical techniques*. New York: Springer 2002; 11.
8. Daniel RK, Calvert JW. Diced cartilage grafts in rhinoplasty surgery. *Plast Reconstr Surg* 2004; 113:2156-2171.
9. Guerrerosantos J, Trabanino C, Guerrerosantos F. Multifragmented cartilage wrapped with fascia in augmentation rhinoplasty. *Plast Reconstr Surg* 2006; 117:804-812.
10. Cerkes N, Basaran K. Diced cartilage grafts wrapped in rectus abdominis fascia for nasal dorsum augmentation. *Plast Reconstr Surg* 2016; 137:43-51.
11. Leaf N. SMAS autografts for the nasal dorsum. *Plast Reconstr Surg* 1996; 97:1249-1252.
12. Wellisz T. Clinical experience with the Medpor porous polyethylene implant. *Aesthetic Plast Surg* 1993; 17:339-344.
13. Regnault P. Nasal augmentation in the problem nose. *Aesthetic Plast Surg* 1987; 11:1-5.
14. Khoo BC. Augmentation rhinoplasty in the orientals. *Plast Reconstr Surg* 1964; 34:81-88.
15. Beekhuis GJ. Silastic alar-columellar prosthesis in conjunction with rhinoplasty. *Arch Otolaryngol* 1982; 108:429-432.

16. Gilmore J. Use of vicryl mesh in prevention of post-rhinoplasty dorsal irregularities. *Ann Plast Surg* 1989; 22:105-107.
17. Godin MS, Waldman SR, Johnson CM. The use of expanded polytetrafluoroethylene (Gore-Tex) in rhinoplasty. A 6-year experience. *Arch Otolaryngol Head Neck Surg* 1995; 121:1131-1136.
18. Queen TA, Palmer FR. Gore-tex for nasal augmentation: A recent series and a review of the literature. *Ann Otol Rhinol Laryngol* 1995; 104:850-852.
19. Adams JS. Grafts and implants in nasal and chin augmentation. A rational approach to material selection. *Otolaryngol Clin North Am* 1987; 20:913-930.
20. Juraha LZ. Experience with alternative material for nasal augmentation. *Aesthetic Plast Surg* 1992; 16:133-140.
21. Gunter JP, Rohrich RJ. Augmentation rhinoplasty: dorsal onlay grafting using shaped autogenous septal cartilage. *Plast Reconstr Surg* 1990; 86:39-45.
22. Lovice DB, Mingrone MD, Toriumi DM. Grafts and implants in rhinoplasty and nasal reconstruction. *Otolaryngol Clin North Am* 1999; 32:113-1141.
23. Vuyk HD, Adamson PA. Biomaterials in rhinoplasty. *Clin Otolaryngol Allied Sci* 1998; 23:209-217.
24. Peer LA. Diced cartilage grafts: New method for repair of skull defects, mastoid fistula and other deformities. *Arch Otolaryngol* 1943; 38:156-165.
25. Cottle MH. Nasal surgery in children. *Eye Ear Nose Throat Mon* 1951; 30:32-38.
26. Burian F. *The plastic surgery atlas*. New York: Macmillan 1968.
27. Erol OO. The Turkish delight: A pliable graft for rhinoplasty. *Plast Reconstr Surg* 2000; 105:2229-2241.
28. Burian F. *The plastic surgery atlas*. New York: Macmillan 1968.
29. Denecke HJ, Meyer R. *Plastic surgery of the head and neck*. New York: Springer 1967; 148.
30. Daniel RK. Diced cartilage grafts in rhinoplasty surgery: Current techniques and applications. *Plast Reconstr Surg* 2008; 122:1883-1891.
31. Rohrich RJ, Muzaffar AR. The Turkish delight: A pliable graft for Rhinoplasty by Ö. Onur Erol. *Plast Reconstr Surg* 2000; 105:2242.
32. Moshaver A, Gantous A. The use of autogenous costal cartilage graft in septorhinoplasty. *Otolaryngol Head Neck Surg* 2007; 137:862-867.
33. Abdullah AF, Khalil AA, Gharib FM, et al. Clinical assessment of solid cartilage versus diced cartilage in fascia in augmentation rhinoplasty. *Menoufia Med J* 2018; 31:229.
34. Peer LA. Extended use of diced cartilage grafts. *Plast Reconstr Surg* 1954; 14:178-185.
35. Kim HK, Chu LS, Kim JW, et al. The viability of diced cartilage grafts wrapped in autogenous fascia and AlloDerm in a rabbit model. *J Plast Reconstr Aesthet Surg* 2011; 193:200-209.
36. Jinli Wu, Donald B. Yoo. An updated diced cartilage fascia technique for dorsal augmentation in rhinoplasty. *Plast Aesthet Res* 2019; 6.
37. Daniel RK. The role of diced cartilage grafts in rhinoplasty. *Aesthetic Surg J* 2006; 26:209-213.
38. Calvert JW, Brenner K, DaCosta-Iyer M, et al. Histological analysis of human diced cartilage grafts. *Plast Reconstr Surg* 2006; 118:230-237.
39. Brenner MJ, Hilger PA. Grafting in rhinoplasty. *Facial Plast Surg Clin North Am* 2009; 17:91-113.
40. Kreutzer C, Hoehne J, Gubisch W, et al. Free diced cartilage: A new application of diced cartilage grafts in primary and secondary rhinoplasty. *Plast Reconstr Surg* 2017; 140:461-470.
41. Trivisonno A, Cohen SR, Magalon G, et al. Fluid cartilage as new autologous biomaterial in the treatment of minor nose defects: Clinical and microscopic difference amongst diced, crushed, and fluid cartilage. *Materials* 2019; 12:1062.
42. Kayabasoglu G, Ozbek E, Yanar S, et al. The comparison of the viability of crushed, morselized and diced cartilage grafts: a confocal microscopic study. *Eur Arch Otorhinolaryngol* 2015; 272:1135-1142.
43. Singh SK, Sood T, Sabarigirish K, et al. A new era of diced cartilage rhinoplasty: Our experience. *Indian J Otolaryngol Head Neck Surg* 2015; 67:338-340.
44. Fedok FG. Costal cartilage grafts in rhinoplasty. *Clin Plast Surg* 2016; 43:201-212.