

## Post-Partum Primary Pulmonary Artery Hypertension (PPPAH): A Rare Obstetrics Complication

Mansi Patel<sup>1\*</sup>, Sourya Acharya<sup>1</sup>, Sunil Kumar<sup>1</sup>, Neema Acharya<sup>2</sup>, Rohan Singh<sup>3</sup>, Shantanu Gomase<sup>4</sup>

<sup>1</sup>Department of Medicine, Jawaharlal Nehru Medical College, Datta Meghe Institute of Medical Sciences and Research (Deemed to be university), Maharashtra, India

<sup>2</sup>Department of Obstetrics and Gynaecology, Jawaharlal Nehru Medical College, Datta Meghe Institute of Medical Sciences and Research (Deemed to be university), Maharashtra, India

<sup>3</sup>Department of Radiodiagnosis, Jawaharlal Nehru Medical College, Datta Meghe Institute of Medical Sciences and Research (Deemed to be university), Maharashtra, India

<sup>4</sup>Department of Cardiology, Jawaharlal Nehru Medical College, Datta Meghe Institute of Medical Sciences and Research (Deemed to be university), Maharashtra, India

### ABSTRACT

Pregnancy is prohibited in cases of pulmonary hypertension (PH), a rare illness that poses a significant risk to both the mother and the fetus. There aren't many written accounts, though, about this illness being diagnosed after delivery. We describe three cases with PH that were discovered following healthy pregnancies and delivery. Although the origins are unknown, a number of mechanisms have been proposed as potential culprits, including hypercoagulation, placental hypoxia, and amniotic fluid embolism. It can be challenging to determine if a postpartum PH diagnosis is related to an earlier asymptomatic PH phase brought on by the physiological stress of labour or if it is a more recent disease.

**Key words:** Postpartum, Pregnancy, Pulmonary hypertension, Sildenafil

**HOW TO CITE THIS ARTICLE:** Mansi Patel, Sourya Acharya, Sunil Kumar, Neema Acharya, Rohan Singh, Shantanu Gomase, Post-Partum Primary Pulmonary Artery Hypertension (PPPAH): A Rare Obstetrics Complication, J Res Med Dent Sci, 2022, 10 (9): 266-268.

**Corresponding author:** Mansi Patel

**e-mail** ✉: mansipatel95@gmail.com

**Received:** 11-Aug-2022, Manuscript No. JRMDs-22-69083;

**Editor assigned:** 13-Aug-2022, PreQC No. JRMDs-22-69083(PQ);

**Reviewed:** 29-Aug-2022, QC No. JRMDs-22-69083(Q);

**Revised:** 02-Sep-2022, Manuscript No. JRMDs-22-69083(R);

**Published:** 09-Sep-2022

### INTRODUCTION

Primary pulmonary hypertension (PHT) is defined as the mean pulmonary artery pressure (mPAP) is greater than 20 mmHg or the pulmonary vascular resistance (PVR) being greater than 3 Wood units [1]. Patients with PHT frequently experience growing exhaustion and breathlessness, which finally evolve into right heart failure. The most prevalent kind of pulmonary hypertension is still Type 2 PHT, which is caused by left heart disease [2,3]. A rare variation of PHT is PPPHT. Within 30 days following delivery is when there is the greatest danger [4].

The combination of a variety of elements may have a role

in the evolution and progression of PPPHT, even if its precise aetiology is still unknown. The function of cardiac output during pregnancy and delivery, auto transfusion from the uteroplacental circulation to the systemic circulation, and the release of uterine pressure on the inferior vena cava after birth abruptly increasing the preload are among the most significant of these factors [6,7]. The second factor is a potential placental hypoxia that releases biological agents that affect vasculature remodeling and vasoconstriction by acting on the endothelium and smooth muscles [8]. Thirdly, although there isn't strong evidence to support it, amniotic fluid embolism during labour that unintentionally entered the pulmonary circulation may cause an inflammatory response that raises pulmonary vascular resistance [9].

Maternal mortality attributable to PTH has significantly decreased from 30–50% to 17–30% as a result of recent breakthroughs in clinical treatments [10].

### CASE REPORT

A 36-year-old female patient presented to this hospital complaining of chest pain and dyspnoea with mild

exertion since 20 days. The chest pain was right-sided, moderate intensity, persistent, stabbing in character and did not radiate. Shortness of breath and palpitations worsened along with the discomfort. Dyspnoea was NYHA grade I initially one month back (associated with moderate exertion) which progressed to NYHA grade III recently (associated with mild exertion). The patient also reported that chest pain was associated with dizziness and fatigue that restricted her ability to take care of her baby. Patient was 1 month postpartum. Delivery was normal full term vaginal with infant having no postpartum distress. She denied fever, orthopnea, paroxysmal nocturnal dyspnoea, or lower limb swelling.

On examination, the patient had tachycardia of 110 beats/min, tachypnoea of 28/min, and had normal blood pressure of 90/70 mm Hg. She required FiO<sub>2</sub> of 44% to maintain normal saturation. JVP was raised at 12 cm of Water; bilateral pitting edema over ankle was present. Six minutes' walk test was done which showed patient could walk upto 4 minutes and she had to take rest due to dyspnea. On respiratory examination: bilateral air entry equal, with basal crepitation was present. Per abdomen examination revealed tender hepatomegaly. There were no evidence of ascites or dilated veins. Central nervous system examination was normal. Cardiovascular examination revealed positive left parasternal heave, diastolic shock, epigastria pulsations. Auscultation revealed grade II ejection systolic murmur over tricuspid area and left 2nd intercostal area, radiating to left 3rd and 4th intercostal spaces. Second heart sound (P2 component) was loud.

ECG revealed features of right ventricular hypertrophy and right axis deviation (Figure 1). Chest x ray revealed dilated pulmonary arteries and cardiomegaly (Figure 2). 2d echo revealed dilated right atrium and ventricle with pulmonary artery with mild TR with PH of 92mmhg with main pulmonary artery hugely dilated, congested IVC with bilateral pleural effusion. Poor biventricular systolic function (Figures 3 and 4).

CT pulmonary angiography revealed right atrial enlargement with cardiomegaly with dilated IVC measuring approx. 28mm in size, reflux of intravenous contrast in IVC and hepatic vein in arterial phase. Pulmonary artery was enlarged measuring 39.29 mm

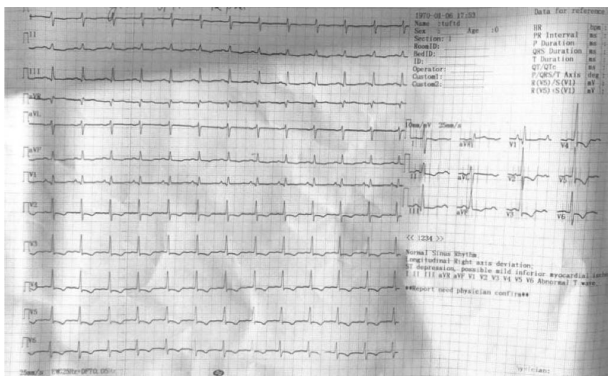


Figure 1: ECG showing right ventricular hypertrophy and right axis deviation.

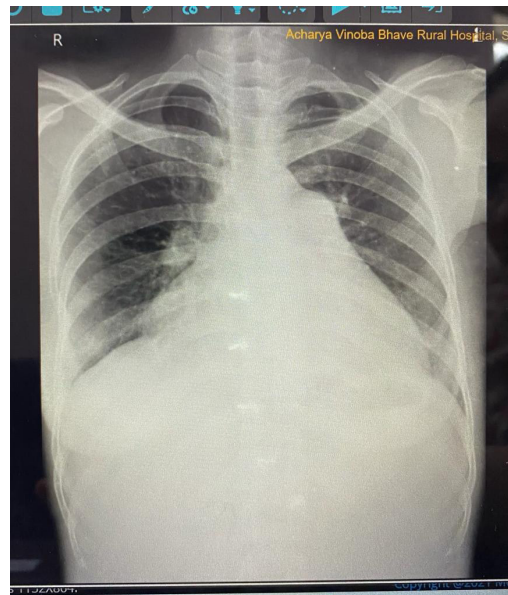


Figure 2: Chest x ray showing dilated pulmonary arteries and cardiomegaly.

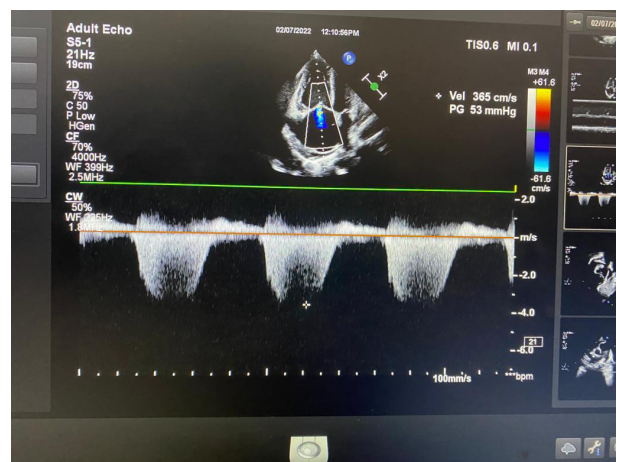


Figure 3: 2d echo revealed severe tricuspid regurgitation.

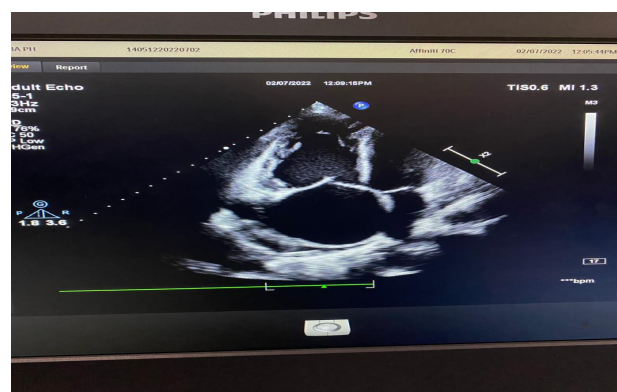
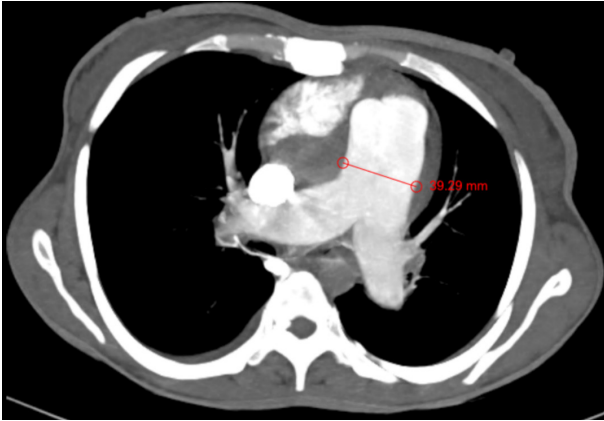


Figure 4: 2d echo revealed dilated right atrium and ventricle.

in size suggestive of pulmonary hypertension with right sided pleural effusion (Figure 5).

Patient was started with endothelial receptor antagonist (tab bosentan 62.5mg OD) and phosphodiesterase-5 inhibitors (tab sildenafil 25mg BD). Patient was improved



**Figure 5:** CT pulmonary angiography axial section of thorax at the level of bifurcation of pulmonary artery revealing dilated pulmonary artery measuring 39.29 mm in diameter.

and was vitally stable. Six minute walk test was again repeated and patient was walking without any signs of distress. Patient was given the treatment therapy for the period of 1 month and was asked to follow up.

#### DISCUSSION AND CONCLUSION

It is simple to overlook postpartum pulmonary hypertension, a rare but dangerous condition. It is crucial to keep this in mind because prompt diagnosis and treatment can significantly reduce a patient's risk of morbidity and mortality [5]. Cardiovascular disease during pregnancy increases the risk of complications and mortality. There is a substantial risk of both maternal and foetal death during pregnancy in women with PAH, which is estimated to be between 30 and 56 percent [6]. Specific PAH treatment improves outcomes, according to a systematic assessment [7] of all published cases of pregnancies in women with PAH between 1997 and 2007. Idiopathic PAH patients' mortality rate dropped from 30% to 17% PAH discovered postpartum appears to be a serious repercussion with an unidentified mechanism. Placental hypoxia, which induces severe vasoconstriction, releases biologically active compounds that affect the development and function of a number of vascular mediators in the endothelium, smooth muscle, and extracellular matrix. Vasoconstriction in the uterine and general circulation also takes place, and vascular remodeling is promoted [9].

It should be emphasized that little is known about pregnancy-induced PAH and that it is unclear how several pathobiological systems interact with one another to cause and advance the disease. The subsequent rise in PVR that led to RV overload, hypertrophy, failure, and mortality has made the medical community more aware of the importance of pulmonary hypertension early identification and treatment, which will improve the patient's result.

#### REFERENCES

1. Braunwald's Heart Disease, 8th ed. Saunders 2008; 1967- 1968.
2. Kuklina EV, Callaghan WM. Cardiomyopathy and other myocardial disorders among hospitalizations for pregnancy in the United States: 2004-2006. *Obstet Gynecol* 2010; 115:93-100.
3. James KB, Healy BP. Heart disease arising during or secondary to pregnancy. *Cardiovasc Clin* 1989; 19:81-96.
4. Weiss BM, Hess OM. Pulmonary vascular disease and pregnancy: current controversies, management strategies, and perspectives. *Eur Heart J* 2000; 21:104-115.
5. Vogiatzis I, Hadjimiltiades S, Sachpekidis V, et al. Spontaneous coronary artery dissection and acute myocardial infarction during pregnancy. *Hellenic J Cardiol* 2010; 51:74-80.
6. Weiss BM, Zemp L, Seifert B, et al. Outcome of pulmonary vascular disease in pregnancy: a systematic overview from 1978 through 1996. *J Am Coll Cardiol* 1998; 31:1650-1657.
7. Bédard E, Dimopoulos K, Gatzoulis MA. Has there been any progress made on pregnancy outcomes among women with pulmonary arterial hypertension? *Eur Heart J* 2009; 30:256-265.
8. Simonneau G, Montani D, Celermajer DS, et al. Haemodynamic definitions and updated clinical classification of pulmonary hypertension. *Eur Respir J* 2019; 53.
9. Simonneau G, Robbins IM, Beghetti M, et al. Updated clinical classification of pulmonary hypertension. *J Am Coll Cardiol* 2009; 54:43-54.
10. Oudiz RJ. Pulmonary hypertension associated with left-sided heart disease. *Clin Chest Med* 2007; 28:233-241.