

# The Use of Tamoxifen in Prevention of Adhesions after Flexor Tendons Surgery in Rabbits

Seyed Mehdi Moosavizadeh<sup>1</sup>, Masoud Yavari<sup>1</sup>, Seyed Esmail Hassanpour<sup>1</sup>, Pajva Soleimanzadeh<sup>1</sup>, Mostafa Alavi<sup>1</sup>, Hormoz Mahmoudvand<sup>2\*</sup>

<sup>1</sup>Department of Plastic Surgery, Khordad Educational Hospital, School of Medicine, Shahid Beheshti University of Medical Sciences, Tehran, Iran

<sup>2</sup>Department of Surgery, Lorestan University of Medical Sciences, Khorramabad, Iran

## ABSTRACT

**Background:** Nowadays, peritendinous adhesions after flexor tendons surgery are still a formidable challenge. In this trial, we aim to assess the effects of oral and local tamoxifen administration in prevention of adhesions after flexor tendons surgery in rabbits.

**Material and Methods:** This study was performed on 40 rabbits (10 animals in each group) underwent flexor tendon incision and then randomly subdivided into four groups. Exploratory incision was done after third postoperative day for macroscopic assessment of adhesions. Finally, we compared the properties of oral and local routes of tamoxifen administration at 2.5 mg/kg/day or both of them with the control group 1.

**Results:** Adhesion characteristic and adhesion tenacity score was measured as the last adhesion mark. The results showed that local tamoxifen was more effective than oral tamoxifen application in prevention of adhesion formation.

**Conclusion:** Our present results confirm that local tamoxifen administration can reduce the postoperative flexor tendon adhesion scores significantly; thus it might have a great benefit in patient's outcome after surgery.

**Key words:** Tamoxifen, Antifibrotic effect, Therapeutic use, Flexor tendon fibrosis

**HOW TO CITE THIS ARTICLE:** Seyed Mehdi Moosavizadeh, Masoud Yavari, Seyed Esmail Hassanpour, Pajva Soleimanzadeh, Mostafa Alavi, Hormoz Mahmoudvand, The use of tamoxifen in prevention of adhesions after flexor tendons surgery in rabbits, J Res Med Dent Sci, 2019, 7(1): 127-130

**Corresponding author:** Hormoz Mahmoudvand

**e-mail:** dmahmodvand@gmail.com

**Received:** 14/12/2018

**Accepted:** 26/01/2019

## INTRODUCTION

Nowadays, peritendinous adhesions after flexor tendons surgery are still a formidable challenge. There are several options for reducing peritendinous adhesions including post-operative rehabilitation therapy, modifications in surgical techniques, pharmacological drugs and mechanical barriers [1]. Recently, the effect of ultrasound, electromagnetic and gene treatment, are also being discovered [1].

Tamoxifen citrate is a mixed agonist/antagonist ligand for the estrogen receptor, widely used to breast cancer therapy [2]. This drug has been shown to inhibit keloid fibroblast proliferation and decrease collagen production [3]. Furthermore, it is approved by the food and drug administration (FDA) for managing of fibroproliferative diseases, like Riedel's thyroiditis, retroperitoneal fibrosis (Ormond's disease) and aggressive fibromatosis (AF or desmoid tumors) [4,5]. Although tamoxifen has been approved for above mentioned fibroproliferative diseases, it may have a little therapeutic effect on the some of them,

such as primary sclerosing cholangitis (PSC) [6], chronic fibrotic kidney disease (CKD) [5], and sclerosing mediastinitis [7].

Here, we hypothesized that tamoxifen through its anti-fibrotic activity might have a potential activity to prevent adhesions after flexor tendons therapy. Therefore in the present investigation we decided to assess the efficacy of oral and local tamoxifen administration in prevention of adhesions after flexor tendons surgery in rabbits.

## MATERIALS AND METHODS

### Ethics

This present experimental investigation was carried out according to the ethical committee in Shaheed Beheshti University of Medical Sciences, Tehran, Iran (No. 1395/2541). The study was performed in accordance with the ethical standards of the 1964 Declaration of Helsinki and its later amendments.

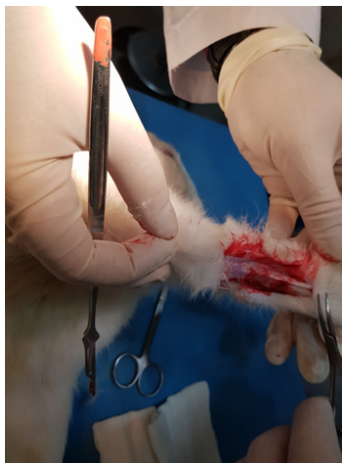
### Animals

Totally 40 rabbits weighing 550 g to 700 g were randomly subdivided into four groups (10 rabbits in each group). All rabbits underwent flexor tendon incision after equal

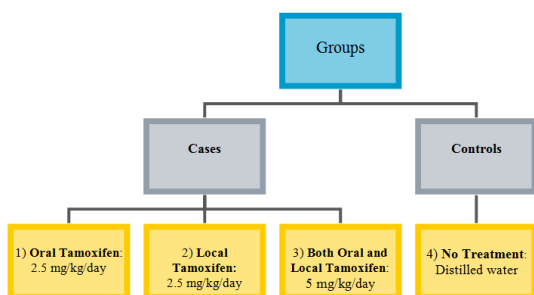
fasting period of four hours. Animals were anesthetized by receiving ketamine (60 mg/kg) and xylazine (5 mg/kg) as well as 1%-2% isofluran using the facial mask.

**Procedure**

At first, the skin was shaved and disinfected, and then incisions in the separate longitudinal midline skin were made on the volar part of the proximal phalanx of each third toe of each front paw and cautiously dissected to contact the synovial sheath (Figure 1). Under magnification with a 4.0X Surgical Loup, the sheath was cut across between the A2 and A3 pulleys for evaluation of the flexor digitorum profundus (FDP) distal to the flexor digitorum superficialis (FDS) bifurcation. The medial aspect of the flexor tendon of the third toe of each front paw was completely divided at the proximal phalanges. Then A 6-0 Nylon revised Kessler suture was located with the knot in the incision mid. After keeping the tendon sheath open, in the next step, the skin was sealed using separated 4-0 Nylon sutures. Finally, the organ was motionless by the wrist flexion, in a spherical cast above the elbow for 21 days.



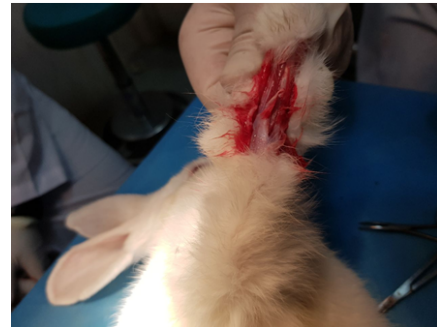**Figure 1: Separate longitudinal midline skin incisions on the volar aspect of the proximal phalanx of the third toe and exposure of the synovial sheath**



**Figure 2: Study flow chart representing study groups**

In group 1 (oral tamoxifen group), 2.5 mg/kg/day tamoxifen citrate was administered by oro-gastric gavage in postoperative phase; group 2 (local tamoxifen group) 2.5 mg/kg of tamoxifen citrate diluted in 10 ml of aquapura was injected into the wound immediately after closure of the tendon sheath; group 3 (both oral and local tamoxifen group) local administration of 2.5 mg/kg

tamoxifen citrate diluted in 10 ml of aquapura, and then 2.5 mg/kg/day tamoxifen citrate was administered by orogastric gavage, postoperatively, in group 4 (control group), distilled water was used as placebo (Figure 2). Rabbits underwent exploratory incision after 21<sup>st</sup> postoperative day (the time of the cast removal) under general anesthesia using 50 mg/kg ketamine chloride. Adhesions were examined macroscopically (Figure 3).



**Figure 3: The synovial sheath was incised transversely between the A2 and A3 pulleys to access the flexor digitorum profundus (FDP) distal to the flexor digitorum superficialis (FDS) bifurcation**

Grading of the adhesions was according to the Adhesion Characteristic and Adhesion Tenacity scoring system (Table 1) [8]. Rabbits were then sacrificed by injecting a boundless dose of thiopental sodium into the heart. Data were analyzed using SPSS for Windows software version 22.0. The sum of two scores Adhesion Characteristic and Adhesion Tenacity score was considered as the final adhesion score and was compared between groups. The Kruskal-Wallis test was utilized to assess the differences in the adhesion score between four groups. A Mann-Whitney-U statistical analysis was also used to determine the differences in adhesion score between four groups, separately. The p values less than 0.05 were considered statistically significant.

**Table 1: Adhesion scoring system**

Adhesion characteristic		Adhesion tenacity	
No adhesion	Grade 0	No resistance to separation	0
25% of surface covered	Grade 1	Moderate to separation	0.5
50% of surface covered	Grade 2	Sharp separation	1
Completely covered	Grade 3	-	-

**RESULTS**

Mean ranks of adhesion scores are presented in Table 2. The Kruskal-Wallis showed significant difference between adhesion scores across the groups (p=0.001). According to the obtained results, the mice in test groups 1-3 revealed statistically significant difference in comparison with the control group (p=0.002). Other results of comparison between groups, using Mann-Whitney-U test, showed that local tamoxifen (group 2) was more effective than group 1 with oral tamoxifen application for prevention of adhesion formation (p=0.004). Also, administration of both oral and local tamoxifen (group 3) reduced the adhesion scores

significantly ( $p=0.003$ ) in comparison with oral administration solely (group 1), but it demonstrated no statistically significant difference ( $p=0.472$ ) with local tamoxifen alone (group 2).

**Table 2: Mean rank of adhesion score in each group based on the adhesion characteristic and adhesion tenacity scoring system**

Group	Mean rank of adhesion score
1	37.3
2	17.9
3	15.8
4	53.2

## DISCUSSION

Here, we hypothesized that tamoxifen through its anti-fibrotic activity might have a potential activity to prevent adhesions after flexor tendons therapy. Thus in the present investigation we decided to assess the efficacy of oral and local tamoxifen administration in prevention of adhesions after flexor tendons surgery in rabbits.

Postoperative adhesion formation results from a cascade of local processes at the trauma site, and may be considered as the pathological part of healing following injury.

Tendons healing can proceed by two mechanisms: intrinsic or extrinsic. Intrinsic healing occurs within the tendon as a result of the activity of tenocytes and appropriate nutrition which is provided by synovial fluid diffusion and allows tendon healing without adhesion formation. Extrinsic healing occurs by the chemotaxis and proliferation of fibroblasts into the defect from the ends of the tendon sheath and usually leads to tendon healing with adhesion. Therefore, adhesions occur because of extrinsic healing of the tendon and limit tendon gliding within fibrous synovial sheaths [9,10].

There are two main strategies for preventing tendon adhesion: the management of damaged tissues and the application of biomaterials [11]. A number of bioresorbable products, in the form of film or fluid, are widely used to prevent postoperative extrinsic healing pathway and the related adhesion formation. The products frequently used in clinic are polylactic acid film (a biodegradable and bioactive thermoplastic aliphatic polyester), Seprafilm (a film composed of chemically modified hyaluronic acid and carboxymethylcellulose), medical sodium hyaluronate, medical chitosan (a linear polysaccharide), Interceed (regenerated cellulose, used only in pelvic surgery) and so on [12].

The use of hyaluronic acid in tendon healing decreased adhesion formation *in vivo*. But, even high molecular weight hyaluronic acid is rapidly eliminated. Thus, Seprafilm came into being by chemical modification of hyaluronic acid to increase its residence time [13]. Seprafilm acts as a physical barrier preventing the formation of adhesions between opposing tissues while the natural process of tissue wound healing takes place

[14]. The effects of the hyaluronic acid in reducing peritendinous adhesion formation can be attributed to their inhibition of fibroblast proliferation and attachment. Hyaluronic acid derivatives such as Seprafilm do not support cell attachment, spreading, or proliferation, because of their negative charge, hydrophilicity, and lack of peptidic epitopes that activate integrins [15]. However, Seprafilm can be difficult to handle during the surgery, especially when wrapping the tendon, because the material loses its integrity and strength during hydration.

Findings of several experimental studies show that tamoxifen can be effective in prevention of postoperative adhesion in abdominopelvic cavity [3,16]. This hypothesis, however, has never been tested in humans [17].

This research is designed based on our previous study [18] on the efficacy of tamoxifen on adhesion formation after abdominal surgery in guinea pigs. Our previous findings demonstrated the worth of tamoxifen in prevention of postoperative intra-abdominal adhesion formation. In this study, the efficacy of tamoxifen administration and its potential benefit in the prevention of adhesions formation after flexor tendons surgery was examined. Our present results are also agreed with the findings of this previous study [18] and the results confirm that both oral and local tamoxifen administration can reduce the postoperative flexor tendon adhesion scores significantly. Previous investigations also demonstrated that tamoxifen citrate is suitable to prevent the peritoneal fibrosis and postoperative intra-abdominal adhesion; whereas its efficacy is dependent on the dose and route of application of this drug [19,20].

Regarding the toxicity of tamoxifen, previous studies have shown that this drug may result in oxidative liver damage and subsequently can cause be hepatocarcinogenic; therefore caution and attention must be considered in human subjects to use the proper doses and subsequently to minimize the side effects [21-25].

## CONCLUSION

Based on the obtained results, the local route administration of the tamoxifen is significantly effective in preventing of adhesion after flexor tendons surgery. Since tendon injuries occurred most often in industry workers with poor compliance to therapies, thus intra-operative tamoxifen local administration might have a great benefit in patient's outcome after surgery and also lower costs and post-surgical complications.

## FUNDING

The authors received no specific funding for this work.

## CONFLICT OF INTEREST

The authors declare that there is no conflict of interest regarding the publication of this manuscript.

## REFERENCES

1. Khanna A, Friel M, Gougoulias N, et al. Prevention of adhesions in surgery of the flexor tendons of the hand: what is the evidence? *Br Med Bull* 2009; 90:85-109.
2. Otaghvar HA, Hosseini M, Tizmaghz A, et al. A review on metastatic breast cancer in Iran. *Asian Pac J Trop Biomed* 2015; 5:429-33.
3. Karaca T, Gözalan AU, Yoldaş Ö, et al. Effects of tamoxifen citrate on postoperative intra-abdominal adhesion in a rat model. *Int J Surg* 2013; 11:68-72.
4. Bonvalot S, Desai A, Coppola S, et al. The treatment of desmoid tumors: A stepwise clinical approach. *Ann Oncol* 2012; 23:158-66.
5. Dellê H, Rocha JR, Cavaglieri RC, et al. Antifibrotic effect of tamoxifen in a model of progressive renal disease. *J Am Soc Nephrol* 2012; 23:37-48.
6. Scapa E, Orda R. Primary sclerosing cholangitis (PSC) and tamoxifen. *Int Hepatol Commu* 1995; 4:149-52.
7. Westerly BD, Johnson GB, Maldonado F, et al. Targeting B lymphocytes in progressive fibrosing mediastinitis. *Am J Respir Crit Care* 2014; 190:1069-71.
8. Linsky CB, Diamond MP, Cunningham T, et al. Adhesion reduction in the rabbit uterine horn model using an absorbable barrier, TC-7. *J Repro Med* 1987; 32:17-20.
9. Howell K, Chien C, Bell R, et al. Novel model of tendon regeneration reveals distinct cell mechanisms underlying regenerative and fibrotic tendon healing. *Sci Rep* 2017; 7:45238.
10. Pauyo T, Herbst E, Fu FH, et al. Tendon healing. In *Muscle and tendon injuries*. Springer 2017; 45-50.
11. Wu W, Cheng R, das Neves J, et al. Advances in biomaterials for preventing tissue adhesion. *J Control Release* 2017; 261:318-36.
12. Lin LX, Yuan F, Zhang HH, et al. Evaluation of surgical anti-adhesion products to reduce postsurgical intra-abdominal adhesion formation in a rat model. *PLoS One* 2017; 12:e0172088.
13. Menderes A, Mola F, Tayfur V, et al. Prevention of peritendinous adhesions following flexor tendon injury with seprafilm. *Ann Plast Surg* 2004; 53:560-4.
14. Diamond MP, Burns EL, Accomando B, et al. Seprafilm® adhesion barrier: (1) A review of preclinical, animal, and human investigational studies. *Gynecological Surg* 2012; 9:237-45.
15. Liu Y, Skardal A, Shu XZ, et al. Prevention of peritendinous adhesions using a hyaluronan-derived hydrogel film following partial thickness flexor tendon injury. *J Orthop Res* 2008; 26:562-9.
16. Oner G, Ulug P. A systemic review of randomized controlled studies about prevention with pharmacologic agents of adhesion formation in the rat uterine horn model. *Arch Med Sci* 2015; 11:274.
17. Pados G, Venetis CA, Almaloğlu K, et al. Prevention of intra-peritoneal adhesions in gynaecological surgery: Theory and evidence. *Reprod Biomed Online* 2010; 21:290-303.
18. Soleymanzadeh P, Mirzaei R, Mahjoubi B, et al. Tamoxifen for the prevention of postoperative intra-abdominal adhesions. *Eur Surg* 2015; 47:65-9.
19. Mohamed AO, Kamar N, Nogier MB, et al. Tamoxifen therapy in kidney-transplant patients presenting with severe encapsulating peritoneal sclerosis after treatment for acute humoral rejection. *Exp Clin Transplant* 2009; 7:164-7.
20. Loureiro J, Sandoval P, del Peso G, et al. Tamoxifen ameliorates peritoneal membrane damage by blocking mesothelial to mesenchymal transition in peritoneal dialysis. *PLoS One* 2013; 8:e61165.
21. Hard GC, Iatropoulos MJ, Jordan K, et al. Major difference in the hepatocarcinogenicity and DNA adduct forming ability between toremifene and tamoxifen in female Crl: CD (BR) rats. *Cancer Res* 1993; 53:4534-41.
22. Athoupa M, Hirsimäki P, Parssinen R, et al. Alterations of drug metabolizing and antioxidant enzyme activities during tamoxifen-induced hepatocarcinogenesis in rats. *Carcinogenesis* 1994; 15:863-8.
23. Kärki A, Mäntylä E, Hirsimäki Y, et al. Comparison of the effects of tamoxifen and toremifene on rat hepatocarcinogenesis. *Arch Toxicol* 2000; 74:249-56.
24. El-Beshbishy HA. The effect of dimethyl dimethoxy biphenyl dicarboxylate (DDB) against tamoxifen-induced liver injury in rats: DDB use is curative or protective. *BMB Rep* 2005; 38:300-6.
25. Desai PB, Nallani SC, Sane RS, et al. Induction of cytochrome P450 3A4 in primary human hepatocytes and activation of the human pregnane X receptor by tamoxifen and 4-hydroxytamoxifen. *Drug Metab Dispos* 2002; 30:608-12.