

## Kidney Injury in Inflammatory Bowel Disease–A Case Report

Devang J Barad\*, P Anandan

Department of General Medicine, Sree Balaji Medical College and Hospital Chromepet, Chennai, Tamilnadu, India

### ABSTRACT

IBD (Inflammatory Bowel Disease) is often associated with several extra-intestinal manifestations, involving various organ systems. It is estimated to be occurring in around 6-47% of IBD patients. Out of these, renal manifestations has an incidence of 4-23%. Simultaneously, conservative management of IBD requires a combination of drugs, including 5-ASAs (5-Aminosalicylates), steroids, antibiotics, immunosuppressive & biologic agents and, it is a known fact that these drugs, namely, 5-ASAs, few immunosuppressant & few biologic agents have known nephrotoxicity. So, in this way, patients of IBD, on treatment, are more prone for kidney injury – either as a part of primary disease process, or as a complication of drug therapy, or both.

Here, we present a case of a 55 years old male with ulcerative colitis for 12 years, admitted with us for acute nephritic syndrome with acute kidney injury (AKI), which was thought to be drug-induced or secondary to both disease-process as well as drug-toxicity.

**Key words:** Acute kidney injury, Immunosuppressant's, Steroids, Antibiotics

**HOW TO CITE THIS ARTICLE:** Devang J Barad, P Anandan, Kidney Injury in Inflammatory Bowel Disease–A Case Report, J Res Med Dent Sci, 2022, 10 (11): 215-217.

**Corresponding author:** Devang J Barad

**e-mail**✉: devangbarad@yahoo.com

**Received:** 25-Oct-2022, Manuscript No. JRMDs-22-75535;

**Editor assigned:** 27-Oct-2022, PreQC No. JRMDs-22-75535(PQ);

**Reviewed:** 10-Nov-2022, QC No. JRMDs-22-75535(Q);

**Revised:** 15-Nov-2022, Manuscript No. JRMDs-22-75535(R);

**Published:** 22-Nov-2022

### INTRODUCTION

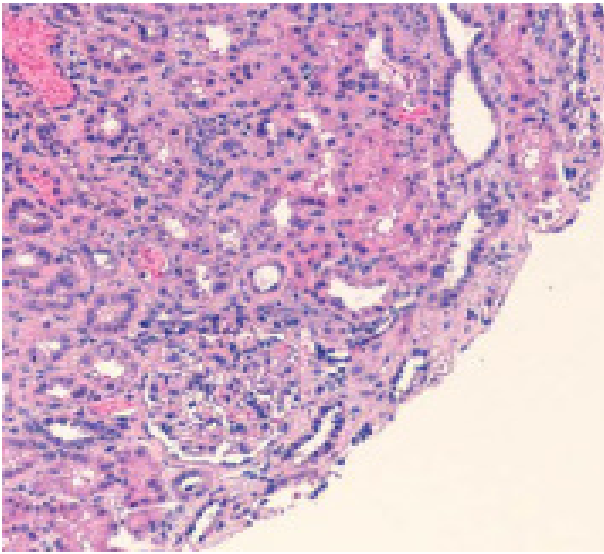
Inflammatory Bowel Disease (IBD), being a systemic inflammatory disorder, thought to be occurring due to abnormal T-cell function, has a wide range of extra-intestinal manifestations. The renal manifestations predominantly include renal calculi, amyloidosis, tubulointerstitial nephritis and glomerulonephritis. These extra intestinal manifestations can be classified as Reactive Manifestations (due to gastrointestinal disease activity), Manifestations Independent of Gastrointestinal Disease Activity (probably due to autoimmune mechanisms) and Metabolic Manifestations (due to factors like malabsorption or bacterial overgrowth) [1]. The basic underlying mechanisms thought to be responsible for these manifestations includes underlying disease activity in the form of chronic systemic inflammation, drug toxicity, secondary to metabolic disorders, malnutrition and others [2].

In a study [3], the most common histological diagnosis of kidney failure in IBD patients includes, in chronological

order, IgA Nephropathy, followed by Tubulointestinal Nephritis (TIN), Arterionephrosclerosis, Acute Tubular Injury, Proliferative Glomerulonephritis, and lastly, Minimal Change Disease. Most of the cases of 5-ASAs exposure were associated with interstitial nephritis. Nephrotoxicity associated with 5-ASAs is a well described entity. It is thought to be an idiosyncratic, delayed type of hypersensitivity with no clear relationship between the duration or dose of the drug and nephrotoxicity. A high index of suspicion, and a prompt and systematic evaluation of AKI in patients of IBD, is hence, of utmost importance to ensure prevention of permanent kidney damage.

### CASE REPORT

A 55 years old male with history of Ulcerative Colitis (UC) for 12 years, on Sulfasalazine, the dose of which was increased 6 weeks back in view of flaring up of disease activity, was admitted with complaints of malaise, and progressive pedal edema for 2 weeks,. There was no history of fever. His previous Renal Function Test (RFT) done 6 weeks back were within normal range. Apart from bilateral pitting pedal edema, physical examination was unremarkable. Routine blood investigations showed elevated urea and creatinine with hypokalemia. Erythrocyte Sedimentation Rate (ESR) was elevated. Urine Routine and Microscopy showed plenty of epithelial cells, plenty of pus cells & presence of RBCs. ABG showed mixed alkalosis. USG abdomen was normal. Urine PCR was elevated. Nephrology



**Figure 1: Kidney Biopsy showing mononuclear interstitial inflammatory infiltrate on interstitial compartment. Foci of acute tubular necrosis foci and tubular hematuria also noted.**

consultation was sought. Serum IgA level was elevated. ANA and Vasculitis profile were negative. Renal Biopsy showed features of Interstitial Nephritis and IgA Nephropathy, which were consistent with sulfasalazine toxicity and extension of disease process of ulcerative colitis, respectively. Sulfasalazine was discontinued and steroids were initiated. Gradually, patients RFT improved over a period of 5 months (Figure 1).

## DISCUSSION

Sulfasalazine is a 5-ASA (5-Aminosalicylic acid) compound that is one of the first line agents in the treatment of IBD. It is used for both induction and maintenance of remission in patients with IBD. Clinically significant kidney injury occurs in 1 in 500 patients treated with sulfasalazine [2-5]. It may present as Tubulointerstitial Nephritis (TIN), or rarely as Minimal Change Disease (MCD). Clinically, it usually has a very vague presentation in the form of malaise, anorexia, weight loss, myalgia, fever, arthralgia, skin rash, etc. Laboratory-wise, there may be blood eosinophilia, asymptotically elevated serum creatinine, sterile leukocyturia, hematuria, low grade proteinuria. 5-ASA toxicity is likely an idiosyncratic dose-independent phenomenon, not related to the drug dosage or duration of exposure to drug.

The proposed mechanism [6] of salicylate induced nephropathy includes high cortical and medullary concentrations of salicylates due to passive resorption throughout the nephron following an active secretion via proximal convoluted tubule via its basolateral and organic anion transporters. Salicylates inhibits prostaglandins, which, in turn, are vasoactive mediators of intra-renal blood flow and are responsible for uncouple oxidative phosphorylation in mitochondria. Thus, dysregulated intrarenal blood flow causing hypoxia, coupled with reduced glutathione levels secondary to inhibition of

pentose phosphate pathway and inflammatory response at endothelial level secondary to recurrent hypoxia/oxygenation injury causes local tissue hypoxia and direct tubular toxicity, which in long run, can contribute to chronic inflammation and tissue hypoxia.

Upon suspected 5-ASA-induced-TIN, there should be prompt discontinuation of the drug. 85% of patients recover to their baseline RFT within 10 months of stoppage of medications [7]. However, 10% may progress to End-Stage Renal Disease (ESRD). 2,4 Steroid and Azathioprine are proposed to be beneficial in 5-ASA-induced-TIN, however, their role is yet to be completely proven.

Regarding follow-up in patients with IBD, who are being treated with 5-ASA, it is proposed that RFT to be checked prior to commencing the treatment. And, after starting the treatment, the patient is to be followed monthly for first 3 months, 3-monthly for the remainder of first year and 6-monthly to yearly thereafter.

With respect to direct renal involvement in IBD patients due to the disease process itself, an association between glomerular deposition of IgA antibodies and intestinal mucosal inflammation has been reported since long [8,9]. It has been seen that a vast number of IBD patients shows occurrence of IgA nephropathy during onset or exacerbation of IBD and as the disease process settles down, subsequent clearance of mesangial IgA deposits has also been demonstrated. The proposed mechanism for IgA nephropathy in IBD patients is the loss of mucosal barrier secondary to mucosal inflammation due to chronic antigenic stimulation and loss of antigenic tolerance and exclusion, leading to increased IgA secreting cells in the intestinal mucosa & subsequent IgA overproduction, causing IgA deposition in glomerular mesangium.

In our case, high clinical suspicion, supported by history and preliminary investigations lead to the early decision of undertaking kidney biopsy, which in-turn, showed features of both acute interstitial nephritis & IgA nephropathy, which, correlated well with drug-induced kidney injury in the backdrop of IBD-associated renal injury.

## CONCLUSION

Renal Injury as an extra intestinal manifestation of IBD is an uncommon but a serious manifestation, which can affect glomerular, tubular or interstitial compartment, either in isolation or in combination. It could be either related to the disease process itself, due to toxicity, or others – in varied combinations. Clinical and laboratory findings guide to the diagnosis, but kidney biopsy proves the diagnosis. High degree of clinical suspicion on the top of early diagnosis by kidney biopsy clarifies the diagnosis & helps in early discontinuation of offending drugs, and thus may help in reversing the kidney injury in early stages.

**CONFLICTS OF INTEREST**

The authors declare no conflict of interest.

**REFERENCES**

1. Ambruzs JM, Walker PD, Larsen CP. The histopathologic spectrum of kidney biopsies in patients with inflammatory bowel disease. *Clin J Am Society Nephrol* 2014; 9:265-270.
2. Corica D, Romano C. Renal involvement in inflammatory bowel diseases. *J Crohns Colitis* 2016; 10:226-235.
3. Oikonomou KA, Kapsoritakis AN, Stefanidis I, et al. Drug-induced nephrotoxicity in inflammatory bowel disease. *Nephron Clin Pract* 2011; 119:89-96.
4. Gisbert JP, González-Lama Y, Maté J. 5-Aminosalicylates and renal function in inflammatory bowel disease: A systematic review. *Inflamm Bowel Dis* 2007; 13:629-638.
5. Campos A, Santos S, Santos J, et al. Mesalazine induced tubulointerstitial nephritis. *Portuguese J Nephrol Hypertens* 2015; 29:158-164.
6. Heap GA, So K, Weedon M, et al. Clinical features and HLA association of 5-aminosalicylate (5-ASA)-induced nephrotoxicity in inflammatory bowel disease. *J Crohn's Colitis* 2016; 10:149-158.
7. Ambruzs JM, Walker PD, Larsen CP. The histopathologic spectrum of kidney biopsies in patients with inflammatory bowel disease. *Clin J Am Soc Nephrol* 2014; 9:265-270.
8. Ambruzs JM, Larsen CP. Renal manifestations of inflammatory bowel disease. *Rheum Dis Clin North Am* 2018; 44:699-714.
9. Saha MK, Julian BA, Novak J, et al. Secondary IgA nephropathy. *Kidney Int* 2018; 94:674-681.